Surgical Treatment of Local Recurrence After Stereotactic Body Radiotherapy for Primary and Metastatic Lung Cancers

Shinya Neri, MD, Yutaka Takahashi, MD, PhD,* Takuya Terashi, MD,* Hiroshi Hamakawa, MD,* Keisuke Tomii, MD, PhD,† Nobuyuki Katakami, MD, PhD,‡ and Masaki Kokubo, MD, PhD§*

Introduction: Stereotactic body radiotherapy (SBRT) has been proposed as an alternative to surgery for the treatment of lung cancer. The treatment of local recurrence that occurs after SBRT has not been reported. We present surgical outcomes for local recurrence following SBRT for primary and metastatic lung cancers.

Methods: Seven of the patients who received SBRT between 2002 and 2008 underwent salvage surgery for local recurrence. These seven patients (two with stage I non-small cell lung cancer and five with metastatic tumors) were operable, although they refused surgery and chose SBRT for the first treatment as a less invasive procedure.

Results: Six of the seven patients underwent lobectomy, and the other patient underwent segmentectomy. None of the seven patients had direct pleural adhesion resulting from SBRT, although, in general, radiation fibrosis occurs after radiotherapy and induces pleural adhesion that makes surgery difficult.

Conclusions: Our study suggests that SBRT may not be the cause of difficulties encountered during the surgical process, and surgery is a good alternative treatment for local recurrence after SBRT. During follow-up after SBRT, the appearance of tumor regrowth on lung images resembled that of inflammatory changes such as radiation pneumonitis. We suggest that close follow-ups should be mandatory after SBRT.

Key Words: Stereotactic body radiotherapy, Non-small cell lung cancer, Metastatic lung cancer, Local recurrence, Salvage surgery.

(*J Thorac Oncol.* 2010;5: 2003–2007)

In recent years, hypofractionated stereotactic body radiotherapy (SBRT) has become available as a novel treatment with low toxicity for patients with stage I non-small cell lung cancer (NSCLC) and pulmonary metastatic tumors.[1–4] Especially in stage I NSCLC, the local control rate is documented to exceed 85%.[1–3] Thus, SBRT could serve as a treatment alternative in patients who are fit to undergo anatomic resection.

Several patterns of disease recurrence after SBRT have been reported.[1,5] These include local recurrence, regional lymph metastasis, and distant metastasis. Resection or repeat SBRT as salvage therapy for such local recurrences has been reported,[5] but few published reports have described the therapeutic management of local recurrence after SBRT. The best therapy for local recurrence is controversial; and therefore, in this study, we report surgical resection for local recurrence after SBRT in a series of patients with stage I NSCLC and pulmonary metastatic tumors.

PATIENTS AND METHODS

Between October 2002 and December 2008, SBRT was performed at our institution on 81 patients with stage I NSCLC and 46 patients with 65 metastatic lesions. Of these, six patients with stage I NSCLC and 12 patients (12 lesions in total) with metastatic tumors had local recurrence. Seven patients (two with stage I NSCLC and five with metastatic tumors) underwent salvage surgery. All seven patients were operable, although they refused surgery and chose SBRT for the first treatment as it is a less invasive procedure. Patient characteristics are summarized in Table 1. We obtained written consent of patients or their families for publishing their clinical data.

Stereotactic Body Radiotherapy

Patients were irradiated using stereotactic techniques, the details of which are described by Onishi et al.[6] In six of the seven patients, a total dose of 48 Gy was administered at the isocenter in four fractions of 12 Gy. In the remaining patient, a total dose of 50 Gy was administered in 10 fractions of 5 Gy, because the tumor was located close to the superior vena cava.

The clinical target volume marginally exceeded the gross target volume by 0 to 5 mm. The planning target volume comprised the clinical target volume, a 2- to 5-mm internal margin and a 0- to 5-mm safety margin. A high dose was concentrated on the tumor-bearing area, while sparing the surrounding normal lung tissues using SBRT.

Departments of *Thoracic Surgery and †Respiratory Medicine, Kobe City Medical Center General Hospital; and Departments of ‡Integrated Oncology and §Image-Based Medicine, Institute of Biomedical Research and Innovation, Kobe, Japan.

Disclosure: The authors declare no conflict of interest.

Address for correspondence: Shinya Neri, MD, Department of Thoracic Surgery, Kobe City Medical Center General Hospital, 4-6 Minatojima-nakamachi, Minato-ku, Kobe 6500046, Japan. E-mail: nerithoracsurg@yahoo.co.jp

Copyright © 2010 by the International Association for the Study of Lung Cancer

ISSN: 1556-0864/10/0512-2003

Copyright © 2010 by the International Association for the Study of Lung Cancer.

TABLE 1. Patient Characteristics and Stereotactic Body Radiotherapy

Case	Age at Surgery (yr)	Gender	Disease	Histology	Location	Radiation Dose (Gy/Fractions)	BED (Gy)
1	78	M	Primary lung cancer	Sq	LUL	48/4	105.6
2	85	M	Primary lung cancer	Sq	LUL	48/4	105.6
3	79	F	Metastatic cancer (colon cancer)	Ad	RLL	48/4	105.6
4	72	F	Metastatic cancer (colon cancer)	Ad	RUL	50/10	75
5	73	M	Metastatic cancer (pharyngeal cancer)	Sq	RUL	48/4	105.6
6	63	M	Metastatic cancer (esophageal cancer)	Ad	RUL	48/4	105.6
7	83	M	Metastatic cancer (colon cancer)	Ad	RLL	48/4	105.6

Ad, adenocarcinoma; BED, biological effective dose; LUL, left upper lobe; RLL, right lower lobe; RUL, right upper lobe; Sq, squamous cell carcinoma.

TABLE 2. Demographic and Treatment Data

	Pre-SBRT			Surgery		Time Interval (mo)		
Case	Tumor Size (mm)	FDG-PET SUVmax	Distance between Tumor Surface and Pleura (mm)	Tumor Size (mm)	FDG-PET SUVmax	Between SBRT and Surgery	Local Control	Surgical Procedure
1	10 × 5	1.8	10	32 × 26 × 24	9.4	8	7	VATS lobectomy
2	15 × 15	7.4	10	40 × 30 × 28	12.2	19	15	Segmentectomy
3	18 × 10	NE	14	40 × 30 × 28	6.8	9	5	Lobectomy
4	14 × 14	3.2	5	30 × 25 × 25	6.0	10	9	Lobectomy with azygos vein resection
5	10 × 10	2.6	28	12 × 10 × 7	3.0	19	18	Lobectomy
6	13 × 13	4.0	30	48 × 45 × 35	NE	25	11	Lobectomy
7	14 × 11	3.2	18	28 × 22 × 15	5.7	8	7	Lobectomy

FDG-PET, [^{18}F]2-fluoro-2-deoxyglucose positron emission tomography; NE, not evaluated; SBRT, stereotactic body radiotherapy; SUVmax, the maximum standardized uptake value; VATS, video-assisted thoracic surgery.

A total dose of 48 or 50 Gy at isocenter was administered with 4-MV x-rays within 20% heterogeneity in the planning target volume dose. No chemotherapy was administered before or during SBRT. The biologic effective dose (BED) was used in a linear-quadratic model.[7] BED was defined as $nd\ (1 + d/\alpha/\beta)$ with gray units, where n is the fractionation number, d is the daily dose, and α/β is assumed to be 10 for tumors (Table 1). Dose constraints were set for the spinal cord only. The BED limit for the spinal cord was 80 Gy (α/β was assumed to be 2 Gy for chronic spinal cord toxicity).

Follow-Ups

After SBRT, we interviewed the patients every 1 to 3 months to determine the presence or absence of symptoms. We also measured serum tumor markers. Lesion characteristics were periodically examined using computed tomography during follow-up visits approximately every 3 months, and [^{18}F]2-fluoro-2-deoxyglucose positron emission tomography (FDG-PET) was performed approximately every 6 months.

RESULTS

The median period of local control after SBRT was 9 months (5–18 months). The median period between SBRT and salvage surgery was 10 months (8–25 months). The median distance between tumor and pleura before SBRT was 14 mm (5–30 mm). The demographic data are summarized in Tables 2 and 3 and Figure 1. Six of the seven patients underwent lobectomy, including one patient with azygos vein resection and one patient with video-assisted surgery. The other patient underwent segmentectomy because of his age and the presence of bullous emphysema. Lobectomy was performed for five patients with metastatic tumors, either because they were located in the hilum of the lung or because they were more than 4 cm in size. Two patients did not achieve complete resection. In one of these patients, multiple nodules in other lobes were detected during the operation, and histologic findings of these were compatible with findings of metastatic cancer. In the other patient, the tumor invaded the chest wall. Between SBRT and surgery, chemotherapy was administered to one of the patients who had esophageal cancer that metastasized to the lung. Another patient developed a postoperative pulmonary fistula, which was treated by surgery and pleurodesis. None of the seven patients had direct pleural adhesion resulting from SBRT, although there was extensive pleural adhesion in the patient with esophageal cancer.

Histopathologic findings revealed viable tumor cells with fibrosis in all irradiated tumors. Some of these tumors were accompanied by necrosis. The tumors were moderately cellular, and they consisted of viable tumor cells with enlarged hyperchromatic nuclei. Because these degenerative changes are common in nonirradiated tumors, the

Copyright © 2010 by the International Association for the Study of Lung Cancer

Copyright © 2010 by the International Association for the Study of Lung Cancer.

TABLE 3. Complications, Lengths of Disease-Free and Follow-Up, Survival, and Histopathologic Findings

Case	Complications: Post-SBRT	Complications: Postsurgery	Disease Free After Surgery (mo)	Follow-Up After Surgery (mo)	Survival	Histopathologic Findings
1	Dermatitis G1[a]	—	32	32	Alive	Viable tumor cells with fibrosis, consistent with lung cancer
2	—	Pulmonary Fistula	2	2	Alive	Viable tumor cells with fibrosis, consistent with lung cancer
3	Pneumonitis G1[a]	—	39	39	Alive	Viable tumor cells with necrosis and fibrosis, consistent with colon cancer
4	—	—	—[b]	25	Alive	Viable tumor cells with necrosis and fibrosis, consistent with colon cancer
5	Pneumonitis G1[a]	—	21	21	Alive	Viable tumor cells with fibrosis, consistent with pharyngeal cancer
6	Pneumonitis G1[a]	—	—[c]	14	Dead	Viable tumor cells with necrosis and fibrosis, consistent with esophageal cancer
7	Pneumonitis G1[a]	—	4[d]	8	Alive	Viable tumor cells with necrosis and fibrosis, consistent with colon cancer

[a] Common terminology criteria for adverse events version 3.0.
[b] Multiple pulmonary metastases.
[c] Invasion of adjacent chest wall.
[d] Regional nodal recurrence.
SBRT, stereotactic body radiotherapy.

tumors did not especially reflect alterations secondary to radiation therapy.

DISCUSSION

This retrospective study analyzed the possibility of salvage therapy for patients who experience locoregional recurrence. In all the cases, we had no difficulty in performing surgery resulting from SBRT. This study, to our knowledge, is the first report specifically describing the outcomes in patients who undergo surgery for local recurrence after SBRT.

In general, radiation can damage the microcirculation by hyalinization of arterioles and fibrosis,[8,9] which induces scar or fibrotic tissues. This often causes adhesion and difficulty in curative resection and anastomosis.

All cases reported in this study had no pleural adhesion due to SBRT. In one of the cases, the extensive pleural adhesion present was probably a result of right-sided thoracotomy for esophageal cancer. Both thoracotomy and video-assisted thoracic surgery could be performed without resulting in severe complications. Thus, SBRT is considered to not cause pleural adhesion or difficulties in curative resection, when compared with conventional radiotherapy. This might be because SBRT is a delivery technique in which a three-dimensional orientation system is used to improve targeting accuracy.

There were no obvious histopathologic alterations attributable to radiation in any of the cases. All the tumors were accompanied by fibrosis. Although the interval between SBRT and surgery was long enough for radiation-induced fibrosis to develop, it was difficult to distinguish between radiation-induced and tumor-induced fibrosis. A few studies have also reported that radiation-induced histologic alterations could not be identified in groups with vestibular schwannoma recurrence after stereotactic radiation.[10,11] It has been proposed that the absence of histopathologic changes can be explained by (1) resistance to global tumor radiation, (2) resistance to radiation in a subpopulation of tumor cells followed by expansion of the resistant clones, or (3) insufficient radiation dosage delivered to tumors.[10] Recently, fibroblasts recruited into caner tissue, called cancer-associated fibroblasts, are frequently observed in the stroma of carcinomas and influence the cancer progression.[12,13] Cancer-associated fibroblasts in the radiation-induced or the tumor-induced fibrosis might contribute to tumor regrowth after SBRT. Further investigations using molecular and genetic techniques are required to better understand the mechanisms of tumor growth suppression and regrowth after SBRT.

In SBRT, a larger tumor volume or lesion originating from colorectal cancer shows poor local control.[5] All the studied tumors were less than 20 mm in diameter before SBRT. Nevertheless, three of the seven tumors were metastatic colon cancers. Once all seven irradiated tumors resulted in disease progression, they grew in size rapidly. Close follow-ups are essential for patients treated with SBRT. If patients have an operable tumor that recurs locally after SBRT, surgical resection can be considered as the first choice of treatment, because surgical treatment in our study was effective for salvage.

During follow-up after SBRT, differential diagnosis of dense consolidation using routine lung computed tomography is very important. The appearance of dense consolidation is a typical characteristic of radiation pneumonitis and fibrosis after SBRT,[14] and it also implies tumor regrowth. To distinguish between inflammatory changes and tumor recurrence, we analyzed serum tumor markers and FDG-PET images. The measurement of tumor markers can be useful for the early detection of cancer. FDG-PET usually shows accumulation resulting from

Copyright © 2010 by the International Association for the Study of Lung Cancer

Copyright © 2010 by the International Association for the Study of Lung Cancer.

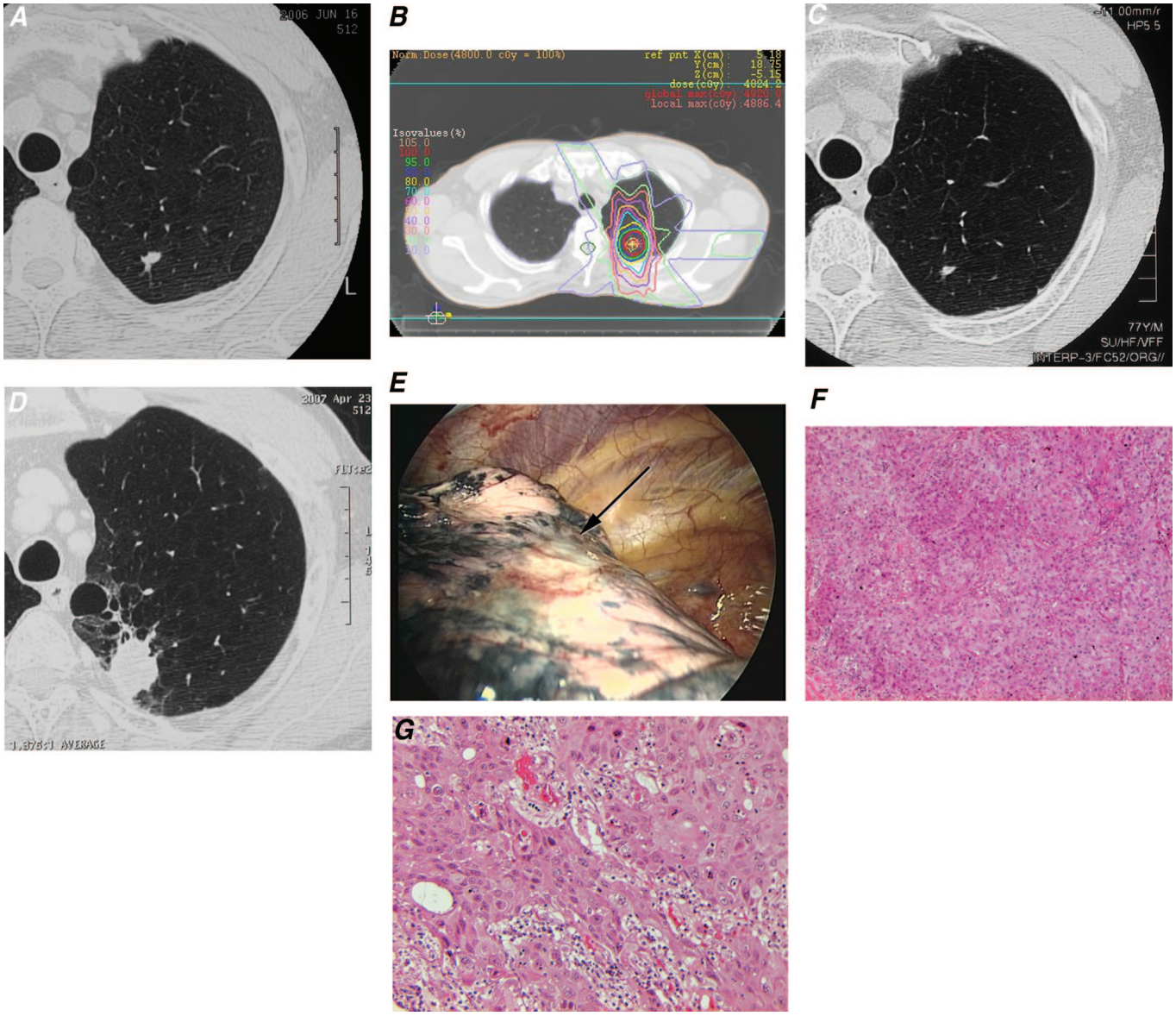

FIGURE 1. Case 1 as a typical example. *A*, High-resolution computed tomography (CT) scan before stereotactic body radiotherapy (SBRT) showing the tumor in the left upper lobe. *B*, Radiation isodose distribution. The tumor is fully enclosed with the 100% dose line (45 Gy, red), and the nearest pleura receives 80% (36 Gy, yellow) of the total dose. *C*, High-resolution CT scan 3 months after SBRT showing a scarred tumor as a partial response. *D*, High-resolution CT scan 7 months after SBRT showing dense consolidation considered as regrowth. *E*, Intraoperative photograph showing the tumor (arrow) without pleural adhesion. *F*, Low-power field showing squamous cell carcinoma with fibrosis (hematoxylin and eosin [HE] stain). *G*, High-power field showing viable tumor cells with enlarged hyperchromatic nuclei and stroma with lymphocyte infiltration (HE stain).

both inflammatory changes and recurrence in the early period after SBRT. Hoopes et al.[15] reported that moderate FDG-PET hypermetabolic activity may persist 1 to 2 years without evidence of recurrence. FDG-PET could be used to assess local and, especially, distant failure after SBRT.

Treatment strategies for local recurrence after SBRT have not received sufficient attention. SBRT is a new and effective treatment option for malignant tumors, especially for stage I NSCLC. This study explored a novel therapeutic strategy for stage I NSCLC—salvage surgery should be performed immediately on detection of local recurrence after prior SBRT treatment. The seven reported cases occurred at a single center. Further research is required to establish the feasibility of surgery for local recurrence after SBRT.

In conclusion, our study suggests that SBRT may not be the cause of difficulties in surgery for local recurrence.

Copyright © 2010 by the International Association for the Study of Lung Cancer

Copyright © 2010 by the International Association for the Study of Lung Cancer.

Because tumor regrowth after SBRT is thought to occur at a rapid rate, close follow-ups should be mandatory for patients treated with SBRT.

REFERENCES

1. Onishi H, Shirato H, Nagata Y, et al. Hypofractionated stereotactic radiotherapy (HypoFXSRT) for stage I non-small cell lung cancer: updated results of 257 patients in a Japanese multi-institutional study. *J Thorac Oncol* 2007;2:S94–S100.
2. Timmerman R, Paulus R, Galvin J, et al. Stereotactic body radiation therapy for inoperable early stage lung cancer. *JAMA* 2010;303:1070–1076.
3. Lagerwaard FJ, Haasbeek CJ, Smit EF, et al. Outcomes of risk-adapted fractionated stereotactic radiotherapy for stage I non-small-cell lung cancer. *Int J Radiat Oncol Biol Phys* 2008;70:685–692.
4. Siva S, MacManus M, Ball D. Stereotactic radiotherapy for pulmonary oligometastases: a systematic review. *J Thorac Oncol* 2010;5:1091–1099.
5. Milano MT, Katz AW, Schell MC, et al. Descriptive analysis of oligometastatic lesions treated with curative-intent stereotactic body radiotherapy. *Int J Radiat Oncol Biol Phys* 2008;72:1516–1522.
6. Onishi H, Araki T, Shirato H, et al. Stereotactic hypofractionated high-dose irradiation for stage I nonsmall cell lung carcinoma: clinical outcomes in 245 subjects in a Japanese multiinstitutional study. *Cancer* 2004;101:1623–1631.
7. Yaes RJ. Defining a uniform biologically effective dose for organs with parallel architecture. *Int J Radiat Oncol Biol Phys* 2000;48:609–611.
8. Inui K, Takahashi Y, Hasegawa S, et al. Effect of preoperative irradiation on wound healing after bronchial anastomosis in mongrel dogs. *J Thorac Cardiovasc Surg* 1993;106:1059–1064.
9. Muehrcke DD, Grillo HC, Mathisen DJ. Reconstructive airway operation after irradiation. *Ann Thorac Surg* 1995;59:14–18.
10. Lee DJ, Westra WH, Staecker H, et al. Clinical and histopathologic features of recurrent vestibular schwannoma (acoustic neuroma) after stereotactic radiosurgery. *Otol Neurotol* 2003;24:650–660; discussion 660.
11. Slattery WH III, Brackmann DE. Results of surgery following stereotactic irradiation for acoustic neuromas. *Am J Otol* 1995;16:315–319; discussion 319–321.
12. Kalluri R, Zeisberg M. Fibroblasts in cancer. *Nat Rev Cancer* 2006;6:392–401.
13. Shimoda M, Mellody KT, Orimo A. Carcinoma-associated fibroblasts are a rate-limiting determinant for tumour progression. *Semin Cell Dev Biol* 2010;21:19–25.
14. Takeda T, Takeda A, Kunieda E, et al. Radiation injury after hypofractionated stereotactic radiotherapy for peripheral small lung tumors: serial changes on CT. *AJR Am J Roentgenol* 2004;182:1123–1128.
15. Hoopes DJ, Tann M, Fletcher JW, et al. FDG-PET and stereotactic body radiotherapy (SBRT) for stage I non-small-cell lung cancer. *Lung Cancer* 2007;56:229–234.

Copyright © 2010 by the International Association for the Study of Lung Cancer

Copyright © 2010 by the International Association for the Study of Lung Cancer.